

Bombesin in Human Neuroendocrine (NE) Neoplasms

GREGORIO CHEJFEC,*¹ INCHUL LEE,[†] WILLIAM H. WARREN[†]
AND VICTOR E. GOULD[†]

*Edward J. Hines, Jr. Veterans Administration Hospital, Department of Laboratory Service
and Associate Professor of Pathology, Loyola University Stritch School of Medicine

[†]Rush Presbyterian St. Luke's Medical Center, Department of Pathology

CHEJFEC, G., I. LEE, W. H. WARREN AND V. E. GOULD. *Bombesin in human neuroendocrine (NE) neoplasms*. PEPTIDES 6: Suppl. 3, 107-112, 1985.— Bombesin is a 14 amino acid peptide isolated from amphibian skin which was found to have stimulatory effects upon gastric and pancreatic secretions, release of gastrointestinal hormones, gallbladder contraction and bronchoconstriction. It is present in amphibian gastric endocrine cells, avian proventriculus endocrine cells and avian brain. In mammals it is present mainly in nerve cells and fibers. The only mammalian endocrine cell shown to date to have bombesin is the P-cell in fetal lung. Bombesin is also found in mammalian brain, with its highest concentration in the hypothalamus. We examined several groups of human neuroendocrine neoplasms for the presence of bombesin by immunohistochemistry. Our findings indicate that bombesin is present 68% of bronchial carcinoids, 65% of pulmonary neuroendocrine carcinomas, 62% of neuroendocrine carcinomas of the skin, 5-10% of pheochromocytomas and extraadrenal paragangliomas and 35% of gastrointestinal carcinoids and neuroendocrine carcinomas. Parallel studies in a wide variety of non neuroendocrine neoplasms failed to reveal the presence of bombesin. We conclude that bombesin is a highly specific marker of neuroendocrine differentiation and thus a valuable tumor marker. Furthermore, its specificity compares favorably with another neuroendocrine marker, neuron specific enolase, an enzyme thought to be present only in neural tissues and neuroendocrine cells but recently found in non neural human tissues and non neuroendocrine neoplasms.

Bombesin Human neuroendocrine neoplasms Immunohistochemistry

BOMBESIN is a tetradecapeptide first isolated from the skin of the discoglossid frog, *Bombina orientalis* [14].

The peptide was shown to have stimulatory effects upon the gastrointestinal and broncho-pulmonary systems. Structurally related peptides were subsequently isolated from the skin of other discoglossid frogs, such as *alytesin* and *ranatensin*, currently referred to as bombesin-like peptides [13].

The biological activity of bombesin has been related to the carboxyl-terminal nine peptide sequence, which is highly conserved in all bombesin-like peptides; the differences among them reside in the amino terminal [39].

The presence of bombesin in tissues has been determined by bioassay, radioimmunoassay and immunohistochemistry. The latter disclosed the presence of bombesin immunoreactivity in endocrine cells of the frog gastric mucosa [27]; cellular localization in amphibian skin has not been determined. Bombesin is also present in amphibian brain, avian proventriculus and brain [15].

A mammalian equivalent of bombesin was described by McDonald *et al.*; they labeled it gastrin releasing peptide (GRP) [30]. This peptide, isolated from porcine stomach and intestine, has 27 amino acid residues and its carboxyl terminal is identical with that of bombesin, except for the single

substitution of histidine for a glutamine residue; a canine analogue has also been purified from intestinal muscle [39].

NORMAL DISTRIBUTION AND PHYSIOLOGICAL ROLE

Mammalian bombesin-like peptides are present mainly in nerve cells and fibers of the gastric mucosa, intestinal muscle layers and prevertebral sympathetic ganglia. The only currently known endocrine cells with bombesin-like immunoreactivity are found in fetal lung; they are absent in normal adult lung [40]. Bombesin-like immunoreactivity has also been found in rat spinal cord and hypothalamus.

Bombesin has been shown to have multiple effects upon gastrointestinal function; intravenous administration in rats stimulates the release of gastrin [31] but does not influence gastric secretion [17]. In dogs, intravenous administration evokes a potent stimulation of gastrin release and acid secretion [5]. Porcine GRP produces a similar response in dogs [30].

Low dose intravenous infusion in healthy human volunteers produced a significant rise in serum gastrin, indicating a marked release stimulatory effect; furthermore the concentrations of bombesin during the experiments were low enough to suggest a physiologic role for the peptide [20].

Stimulation of protein rich pancreatic secretion and

¹Requests for reprints should be addressed to Dr. Gregorio Chejfec, M.D., Edward J. Hines, Jr. Veterans Administration Hospital, Department of Laboratory Service (113), Hines, IL 60141.

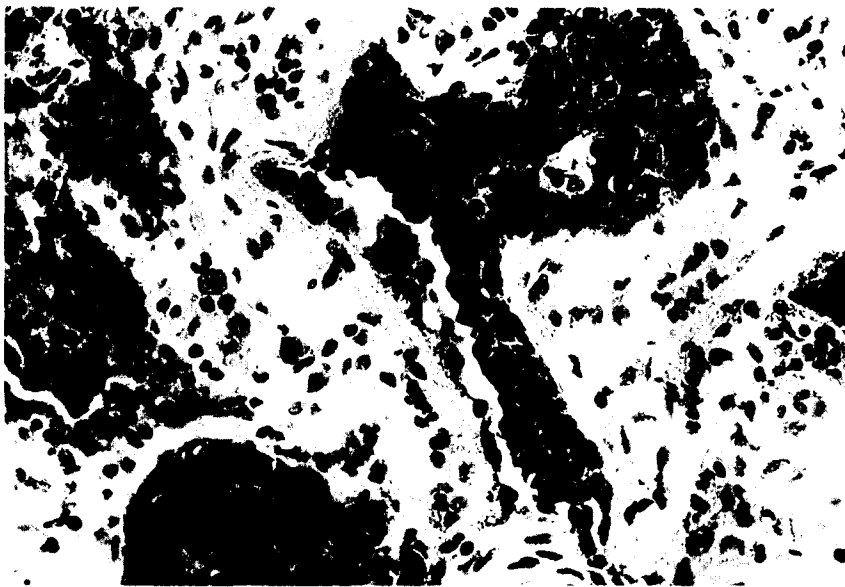


FIG. 1. Bombesin immunoreactivity in pulmonary tumorlet in an area of scarring. (Immunoperoxidase $\times 600$).

gallbladder contraction by intravenous injection of bombesin has been demonstrated in dogs [16] and humans [1], suggesting that these effects are caused through the release of cholecystokinin.

In rats and guinea pigs, bombesin may have a direct action upon pancreatic acinar cells; presumably these cells have different receptors for bombesin and cholecystokinin [25]. This stimulation causes the release of pancreatic enzymes and outflux of cellular calcium.

Gastrointestinal hormones are similarly released by bombesin infusion; in dogs it releases not only gastrin but pancreatic polypeptide, enteroglucagon, pancreatic glucagon and gastric inhibitory polypeptide [29].

In humans, bombesin infusions caused significant rises in plasma insulin, glucagon, pancreatic polypeptide, gastrin, cholecystokinin, motilin, glucose-dependent insulinotropic polypeptide, neurotensin, enteroglucagon, vasoactive intestinal polypeptide and serum calcium; concomitantly, there was a significant fall in parathyroid hormone concentration and blood glucose. There were no significant changes in pituitary hormone plasma concentrations [20]. In this regard, bombesin has an opposite effect to somatostatin, which inhibits the release of gastrointestinal hormones.

Gastrointestinal motility and smooth muscle contraction are also stimulated by bombesin infusions which also produce contraction of the distal stomach with relaxation of the proximal stomach, loss of small bowel motility, contraction of the ileocecal valve and some loss of colonic activity in normal human subjects [6]. These effects are thought to be caused by direct action on smooth muscle cells although other indirect mediators have been implied [39].

In some species, bombesin may also influence blood pressure, renal function, urinary bladder and bronchiolar muscle. In dogs, the rennin angiotensin system is activated when bombesin is infused in association with vasoconstriction of afferent renal arterioles and decreased diuresis [18]. In guinea pigs it causes urinary bladder smooth muscle contraction [38]; and bronchiolar muscle spasm [34].

Bombesin also has a wide range of pharmacological ac-

tions upon the central nervous system. It lowers body temperature in rats, an effect accentuated by exposure to a cold environment: the site of action of bombesin was located in the preoptic area of the anterior hypothalamus by microinjection experiments. At high ambient temperatures, intraventricular injection of bombesin causes hyperthermia.

Another significant effect on the central nervous system is the elevation of blood sugar in response to intracisternal injections of bombesin in conscious rats; this is accompanied by elevation of glucagon and relative decrease in plasma insulin. These responses are prevented by adrenalectomy but not by hypophysectomy, indicating a primary effect in the brain to increase sympathetic outflow to the adrenal gland, causing increased secretion of epinephrine and hyperglycemia [8].

Finally bombesin has a role in the modification of feeding behavior; intraperitoneal injections of bombesin in rats causes inhibition of liquid and solid food intake in conscious rats [2]. This satiety was accompanied by other behavioral changes, such as grooming and lethargy.

BOMBESIN IN PATHOLOGIC STATES

The role of bombesin in pathological states has been the subject of a number of investigations. The earliest application was a natural derivation from its best known and most potent physiological and pharmacological action, namely that of a gastrin releasing hormone.

Bombesin infusion was proposed as a diagnostic test for hypergastrinemic states, successfully identifying a group of patients with residual antral syndrome [2] and gastrinomas of pancreatic and duodenal origin [28].

The initial observation of bombesin-like immunohistochemical reactivity in endocrine cells of the intrapulmonary fetal bronchial epithelium opened the way for studies in pulmonary pathology. Bombesin was not found in significant amounts in human lungs beyond the neonatal state and was totally absent in the normal adult lung by immunohistochemical methods [40] and RIA [11]. It was mark-

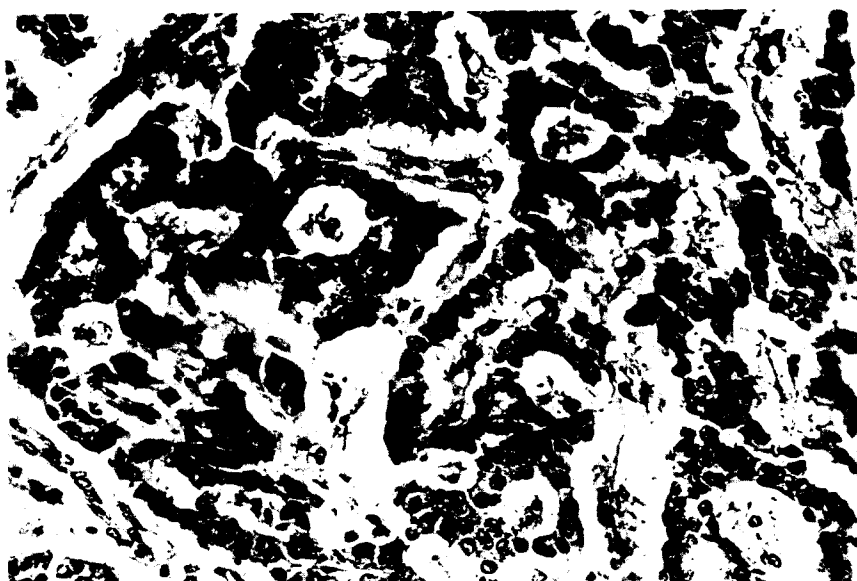


FIG. 2. Typical bronchial carcinoid with diffuse bombesin immunoreactivity. (Immunoperoxidase $\times 600$).

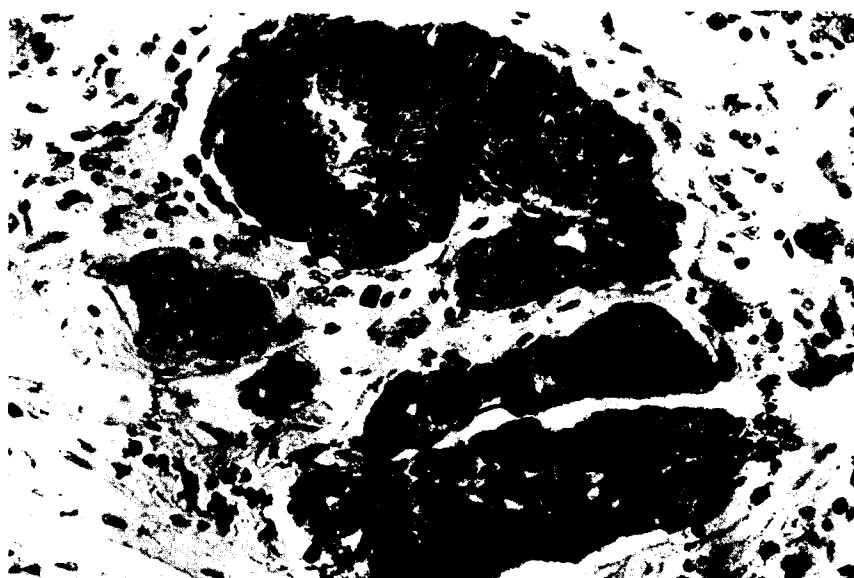


FIG. 3. Bombesin immunoreactivity in well differentiated neuroendocrine carcinoma of the lung. (Immunoperoxidase $\times 600$).

edly decreased in the neonatal acute respiratory distress syndrome [19–26]. In contrast with the acute syndrome, the number of bombesin immunoreactive endocrine cells was markedly increased in the lungs of infants with IRDS (idiopathic respiratory distress syndrome) who survived over 3 weeks and who were kept in respirators [37]. In the adult lung, chronic hypoxia associated with emphysema and bronchiectasis has been shown to be associated with an increase in endocrine cells by immunohistochemistry [32]. In our laboratory, we have carried out observations on samples of bronchial mucosa from lung specimens excised for carcinoids and carcinomas. Immunohistochemical studies with

bombesin demonstrated an increase in the number of solitary bronchial neuroendocrine cells and neuroepithelial bodies (NEB), as well as rows of neuroendocrine cells ("linear hyperplasia") [23].

Neoplastic neuroendocrine cells have also been shown to have immunoreactive bombesin, having been demonstrated in tumorlets and microcarcinoids [22–23] (Fig. 1). The initial observation of high levels of bombesin in continuous tissue culture lines of small cell carcinoma of the lung, determined by high performance liquid chromatography, led the authors to postulate that the presence of bombesin was an essential growth factor ("autocrine factor") for these cancer cells; it

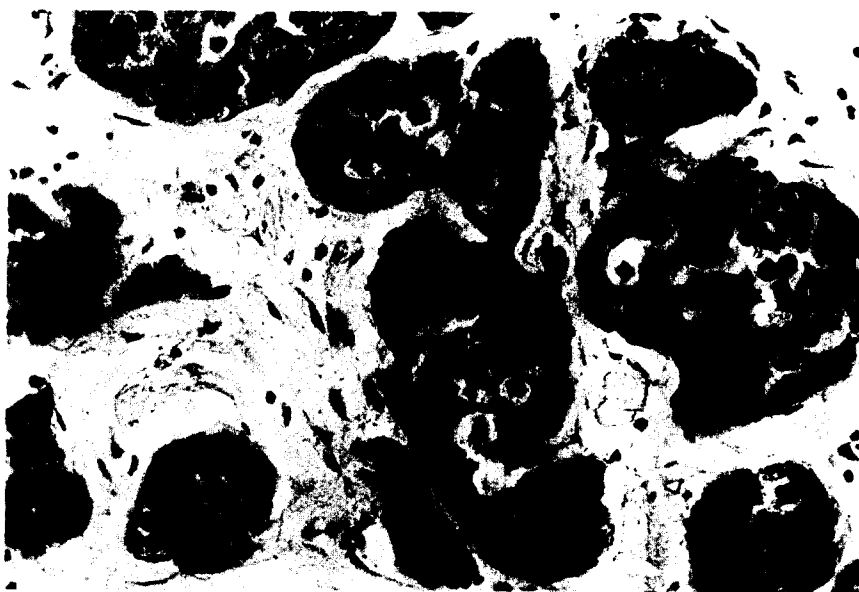


FIG. 4. Neuroendocrine carcinoma of the skin (Merkel) with diffuse immunoreactivity for bombesin. (Immunoperoxidase $\times 600$).




FIG. 5. Carotid body tumor with bombesin immunoreactivity. (Immunoperoxidase $\times 600$).

also was a clue to the nature of the precursor cell. None of the culture lines of other types of pulmonary carcinomas contained detectable levels of bombesin [33]. It affirmed earlier observations which suggested that pulmonary oat cell carcinomas "derived" from or differentiate towards endocrine cells of the lung [4]. Study of a human small cell carcinoma, grown in nude mice, extended the observations, demonstrating the presence of bombesin by RIA, immunohistochemistry, gel filtration and reverse-phase high performance liquid chromatography [12].

Other types of pulmonary endocrine neoplasias were also shown to contain bombesin; its presence was demonstrated in bronchial carcinoid tumors [7,41] (Fig. 2), atypical

endocrine tumor of the lung [10], well differentiated (Fig. 3) and intermediate type neuroendocrine carcinomas of the lung [7].

Recently a number of bronchioloalveolar carcinomas were proven to contain bombesin; the authors suggested that these neoplasias had a heterogeneous cell population, most probably arising from immature mucous cells and occasionally from type II cells which only secrete surfactant [39]. The suggestion was made that bombesin may not be entirely specific for neuroendocrine tumors [35]. We also examined a case of bronchioloalveolar carcinoma, which was positive for bombesin and displayed neurosecretory granules as well as mucosubstance by electron microscopy. It belonged to a

TABLE 1
NEUROENDOCRINE CARCINOMAS: BOMBESIN
IMMUNOHISTOCHEMICAL REACTIVITY

	Number of Cases Tested	Number of Positive Cases %
Bronchial carcinoid	31	21
Pulmonary intermediate cell carcinoma	12	6
Pulmonary small cell carcinoma	7	1
Pulmonary neuroendo- crine well differ- entiated carcinoma	15	10
Skin neuroendocrine carcinoma, trabecu- lar type	4	2
Skin neuroendocrine carcinoma, inter- mediate cell type	9	4
Skin neuroendocrine carcinoma, small cell type	9	4
Carotid body tumors	4	2
Glomus tympanicum	11	1
Glomus jugulare	4	1
Pheochromocytomas	3	0
Malignant melanomas	13	1
Gastrointestinal car- cinoids	3	1
Gastrointestinal neuroendocrine carcinomas	2	1
	9	2

group of amphotericine carcinomas characterized by single cell synchronous co-expression of exocrine and endocrine differentiation [9].

Our interest in this subject prompted us to broaden the scope of our immunohistochemical studies, extending them to the neuroendocrine neoplasias arising in different anatomical sites.

Thus, we examined by immunohistochemistry [38] a group of hyperplasias, dysplasias and neoplasms associated with neuroendocrine (Merkel) cells of the skin: bombesin was present in hyperplasias and dysplasias as well as in all the morphologic variants (trabecular, intermediate cell and small cell type) of neuroendocrine skin carcinomas [24] (Fig. 4). Similarly, carotid body tumors (Fig. 5), glomus tympanicum, glomus jugulare, pheochromocytomas, extra-adrenal paragangliomas, malignant melanomas and neuroendocrine carcinomas of the gastrointestinal tract were analyzed and found to have bombesin in varying proportions (see Table 1).

SUMMARY AND CONCLUSIONS

We investigated the presence of bombesin in a wide variety of human neuroendocrine neoplasms and found it to be present in a significant number. Parallel studies demonstrated its absence in various types of non neuroendocrine neoplasms. Thus we believe that the presence of bombesin is highly specific for neuroendocrine cellular differentiation and therefore an excellent marker for these neoplasms. Furthermore, the specificity of bombesin compares favorably with neuron specific enolase, also present in neuroendocrine cells and currently held to be a specific neuroendocrine tumor marker, but recently found in non neural human tissues and non-neuroendocrine neoplasms [36].

ACKNOWLEDGEMENTS

Technical collaboration: Ben Booker and Mariann Eichorst. We thank Mrs. Corrine Arthur for the typing of the manuscript.

REFERENCES

1. Basso, N., S. Giri, G. Importa, E. Lezoche, P. Melchiorri, M. Percoco and V. Speranza. External pancreatic secretion after bombesin infusion in man. *Gut* 16: 994-998, 1975.
2. Basso, N., E. Lezoche, S. Giri, M. Percoco and V. Speranza. Acid and gastrin levels after bombesin and calcium infusion in patients with incomplete antrectomy. *Am J Digest Dis* 22: 125-128, 1977.
3. Bedrossian, C., N. Ordonez, A. Glick, A. G. Kasselberg and G. Singh. Immunocytochemical and ultrastructural correlations in bronchoalveolar carcinomas. *Lab Invest* 48: 8A-9A, 1983.
4. Bensch, K. G., B. Corrin, R. Pariente and H. Spencer. Oat cell carcinoma of the lung: its origin and relationship to bronchial carcinoid. *Cancer* 22: 1163-1169, 1968.
5. Bertaccini, G., V. Erspamer, P. Melchiorri and N. Sopranzi. Gastrin release by bombesin in the dog. *Br J Pharmacol* 52: 219-225, 1974.
6. Bertaccini, G., M. Impicciatore, E. Molina and L. Zappia. Action of bombesin on human gastrointestinal motility. *Rendic Gastroenterol* 6: 45-51, 1974.
7. Blobel, G. A., V. E. Gould, R. Moll, I. Lee, M. Huszar, B. Geyer and W. W. Franke. Coexpression of neuroendocrine markers and epithelial cytoskeletal proteins in bronchopulmonary neuroendocrine neoplasms. *Lab Invest* 52: 39-51, 1985.
8. Brown, M., Y. Tache and D. Fisher. Central nervous system action of bombesin: Mechanism to induce hyperglycemia. *Endocrinology* 105: 660-665, 1979.
9. Chejfec, G., C. Capella, E. Solcia, J. Jao and V. E. Gould. Amphotericine cells, dysplasias and neoplasias. *Cancer*, in press.
10. Chorba, T., J. M. Orenstein, L. Harisiadis, T. Moody, T. Burton and R. S. Schulof. An atypical endocrine tumor of the lung responsive to radiation therapy and 5-Fluorouracil-Streptozotocin. *Cancer* 53: 2430-2438, 1984.
11. Cutz Chans, W. and N. S. Track. Bombesin, calcitonin and leu-enkephalin immunoreactivity in endocrine cell of human lung. *Experientia* 37: 765-767, 1981.
12. Erisman, M. D., R. Ilona Linoila, O. Hernandez, R. P. Di-Augustine and L. H. Lazarus. Human lung small-cell carcinoma contains bombesin. *Proc Natl Acad Sci USA* 79: 2379-2383, 1982.
13. Erspamer, V. Peptides of the amphibian skin active on the Gut II. Bombesin-like peptides: Isolation, structure and basic functions. In: *Gastrointestinal Hormones*, edited by G. B. Jerzy Glass. New York: Raven Press, 1980, pp. 343-361.

14. Erspamer, V., G. Falconieri Erspamer, M. Inselvini and L. Negri. Occurrence of bombesin and alytesin in extracts of the skin of three European discoglossid frogs and pharmacological actions of bombesin on extravascular smooth muscle. *Br J Pharmacol* 45: 333-348, 1972.
15. Erspamer, V., G. Falconieri Erspamer, P. Melchiorri and L. Negri. Occurrence and polymorphism of bombesin-like peptides in the gastrointestinal tract of birds and mammals. *Gut* 20: 1047-1056, 1979.
16. Erspamer, V., G. Improta, P. Melchiorri and N. Soprani. Evidence of cholecystokinin release by bombesin in the dog. *Br J Pharmacol* 52: 227-232, 1974.
17. Erspamer, V., P. Melchiorri, C. Falconieri Erspamer and L. Negri. Polypeptides of the amphibian skin active on the gut and their mammalian counterparts. In: *Gastrointestinal Hormones and Pathology of the Digestive System*, edited by M. E. Grossman, V. Speranza, N. Basso and E. Lezoché. New York: Plenum, 1978, pp. 51-65.
18. Erspamer, V., P. Melchiorri and N. Soprani. The action of bombesin on the kidney of the anesthetized dog. *Br J Pharmacol* 48: 438-455, 1973.
19. Ghatei, M. A., M. N. Shepard, S. Henzen-Logman, M. A. Blank, J. Polak and S. R. Bloom. Bombesin and vasoactive intestinal polypeptide in the developing lung: marked changes in acute respiratory distress syndrome. *J Clin Endocrinol Metab* 57: 1226-1232, 1983.
20. Ghatei, M. A., R. T. Jung, J. C. Stevenson, C. J. Hillyard, T. E. Adrian, Y. C. Lee, N. D. Christofides, D. L. Sarson, K. Mashiter, I. MacIntyre and S. R. Bloom. Bombesin: Action on gut hormones and calcium in man. *J Clin Endocrinol Metab* 54: 980-985, 1982.
21. Gibbs, J., D. J. Fauser, E. A. Rowe, B. J. Rolls and S. P. Maddison. Bombesin suppresses feeding in rats. *Nature* 282: 208-210, 1979.
22. Gould, V. E. *The Endocrine Lung*. Edit *Lab Invest* 48: 507-508, 1983.
23. Gould, V. E., R. I. Linoila, V. A. Memoli and W. H. Warren. Neuroendocrine components of the bronchopulmonary tract: Hyperplasias, dysplasias and neoplasms. *Lab Invest* 49: 519-537, 1983.
24. Gould, V. E., R. Moll, I. Moll, I. Lee and W. W. Franke. Neuroendocrine (Merkel) cells of the skin: Hyperplasias, dysplasias and neoplasias. *Lab Invest* 52: 334-353, 1985.
25. Jensen, R. T., T. Moody, C. Pert, M. Brown, J. R. Rivier and J. D. Gardner. Interaction of bombesin and litorin with specific membrane receptors on pancreatic acinar cells. *Scand J Gastroenterol [Suppl]* 13: 94-98, 1978.
26. Johnson, D. E., J. E. Lock, R. P. Elde and T. E. Thompson. Pulmonary neuroendocrine cells in hyaline membrane disease and bronchopulmonary dysplasia. *Pediatr Res* 16: 446-450, 1982.
27. Lechago, J., A. L. Holmquist and J. H. Walsh. Localization of a bombesin-like peptide in frog gastric mucosa by immunofluorescence and R.I.A. *Gastroenterology* 74: 1054, 1978.
28. Lezoché, E., N. Basso and V. Speranza. Action on bombesin in man. In: *Gut Hormones*, edited by S. R. Bloom and J. M. Polak. New York: Churchill Livingstone, 1981.
29. McDonald, T. J., M. A. Ghatei, S. R. Bloom, N. S. Track, J. Radziuk, J. Dupre and V. Mutt. A quantitative comparison of canine plasma gastroenteropancreatic hormone responses to bombesin and porcine gastrin releasing peptide. *Regul Pept* 2: 293-304, 1981.
30. McDonald, T. J., G. Nilsson, M. Vagne, M. Ghatei, S. R. Bloom and V. Mutt. A gastrin releasing peptide from the porcine non-antral gastric tissue. *Gut* 19: 767-774, 1978.
31. Martindale, R., G. L. Kauffman, S. Levin, J. H. Walsh and T. Yamada. Differential regulation of gastrin and somatostatin secretion from isolated perfused rat stomachs. *Gastroenterology* 83: 240-244, 1982.
32. Memoli, V. A., I. Linnoila, W. H. Warren, J. Rios-Dalenz and V. E. Gould. Hyperplasia of pulmonary neuroendocrine cells and neuroepithelial bodies. *Lab Invest* 48: (abstr) 57A, 1983.
33. Moody, T. W., C. B. Pert, A. F. Gazdar, D. N. Carney and J. D. Minna. High levels of intracellular bombesin characterize human small-cell lung carcinoma. *Science* 214: 1246-1248, 1981.
34. Polak, J. and S. R. Bloom. Neural and cellular origin of gastrointestinal hormones. Peptides in health and disease. In: *Gastrointestinal Hormones*, edited by G. B. Jerzy Glass. New York: Raven Press, 1980, pp. 19-48.
35. Said, J. W., S. Vimadal, G. Nash, I. P. Shintaku, R. C. Heusser, A. F. Sassoon and R. V. Lloyd. Immunoreactive neuron-specific enolase bombesin and chromogranin as markers for neuroendocrine lung tumors. *Hum Pathol* 16: 236-240, 1985.
36. Schmechel, D. E. γ Subunit of the glycolytic enzyme enolase: Nonspecific or neuron specific? *Invest* 52: 239-242, 1985.
37. Stahlman, M. T., A. G. Kasselberg, D. N. Orth and M. E. Gray. Ontogeny of neuroendocrine cells in human fetal lung. *Lab Invest* 52: 52-60, 1985.
38. Sternberger, L. A. *Immunocytochemistry*. 2nd edition. New York: John Wiley and Sons, 1979.
39. Walsh, J. bombesin-like peptides. In: *Brain Peptides*, edited by D. T. Krieger, M. J. Brownstein and J. B. Martin. New York: John Wiley and Sons, 1983.
40. Wharton, J., J. M. Polak, S. R. Bloom, M. A. Ghatei, E. Solcia, M. R. Brown and A. G. E. Pearse. Bombesin-like immunoreactivity in the lung. *Nature* 273: 769-770, 1978.
41. Yang, K., T. Ulich, I. Taylor, L. Cheng and K. J. Lewin. Pulmonary carcinoids. Immunohistochemical demonstration of brain gut peptides. *Cancer* 52: 819-823, 1983.